

2<sup>nd</sup> ALEXANDRIA  
OPHTHALMOLOGY SUMMIT

Alexandria University | Ophthalmology Department  
24 - 26 April, 2019 | Radisson Blu Hotel, Alexandria, Egypt

# Refractory Macular Edema

## How to Manage??

---

By  
Tarek Hemeida, MD.  
Armed-Forces Hospital, Alexandria  
Assoc. Prof. Military Medical Academy.

**74 year old Male.**

**Seeking Second Opinion. 6 IV-Ranibizumab Inj.,**

**Recommended to Shift Anti-VEGF.**

**POHx: PC-IOL 5ys.**

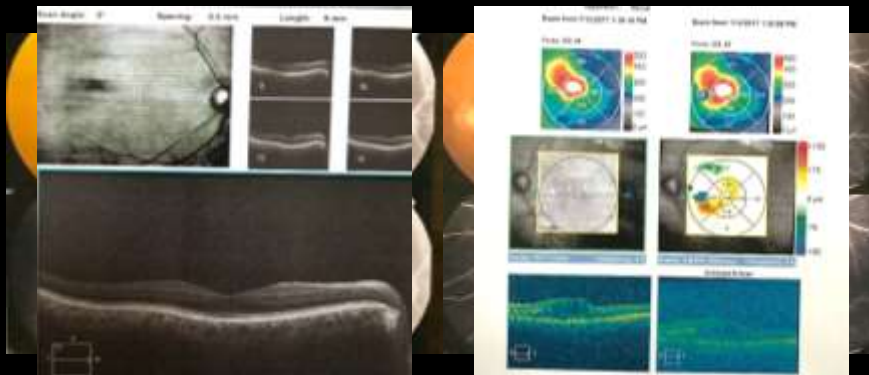
**PMHx: Type II DM 20ys, HTN 10ys, IHD 12ys, Benign Prostatic hyperplasia.**

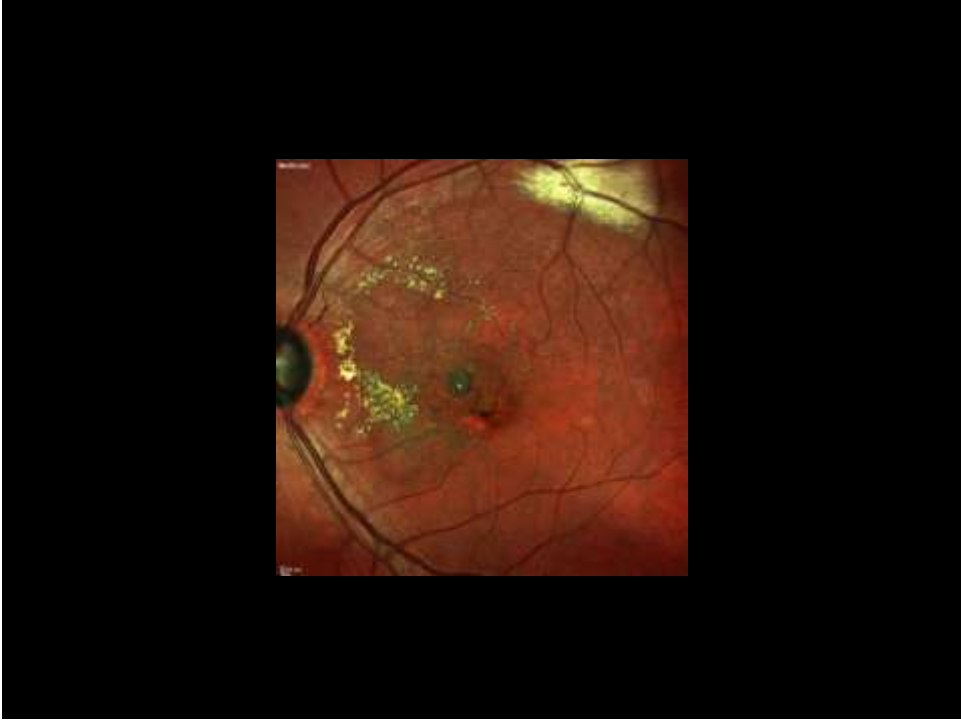
**Systemic and Ocular Meds: Oral Hypoglycemic,  $\beta$ - Blocker, Vasodilators,  $\alpha$ -blockers .**

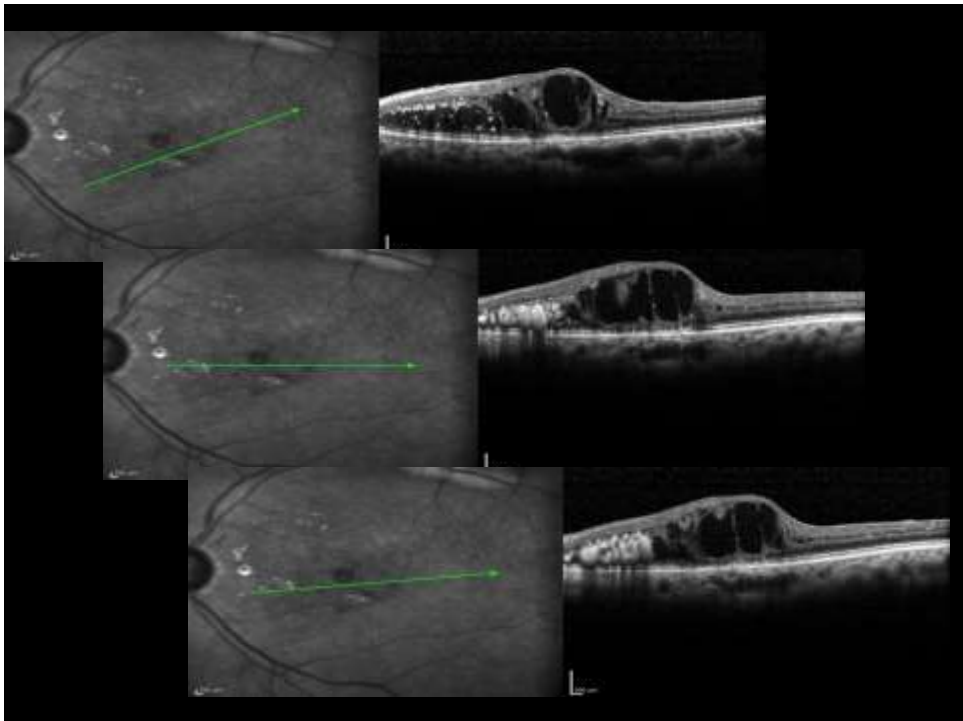
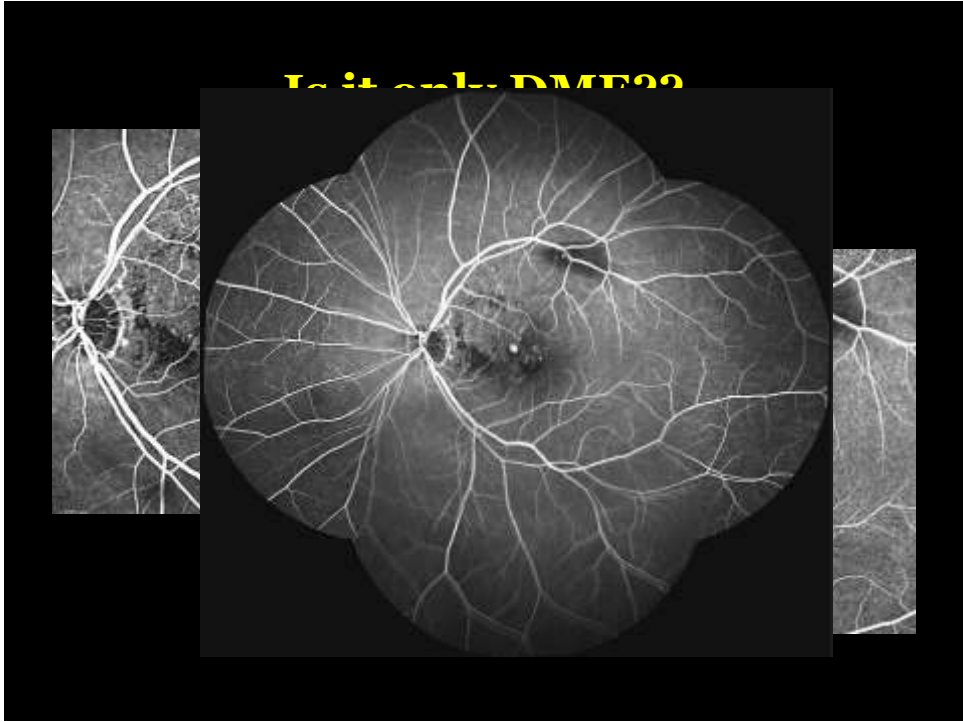**Allergies: None**

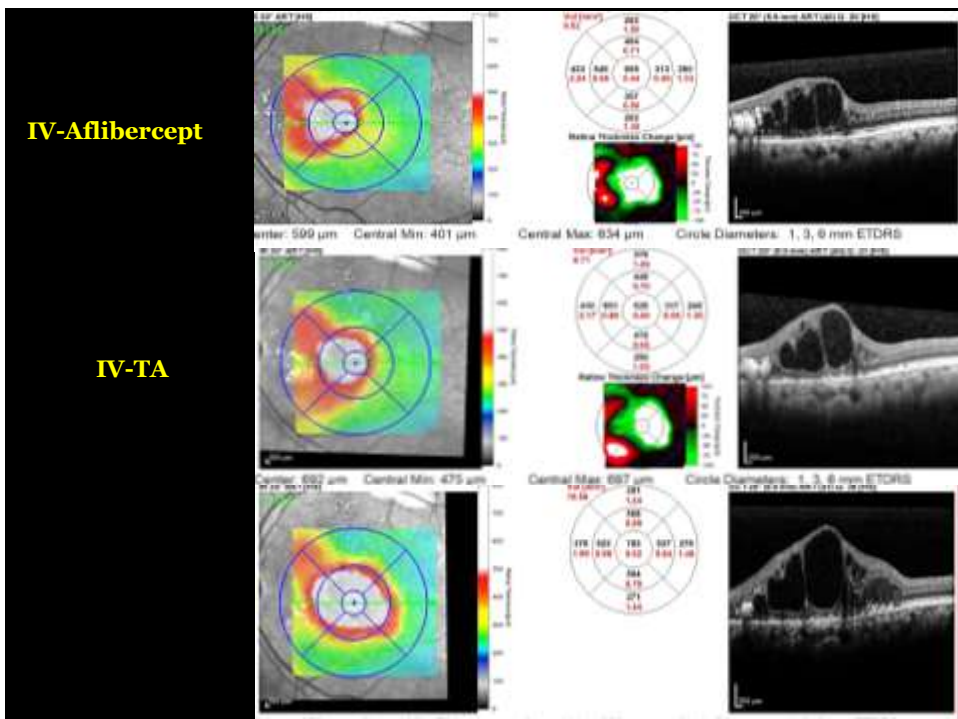
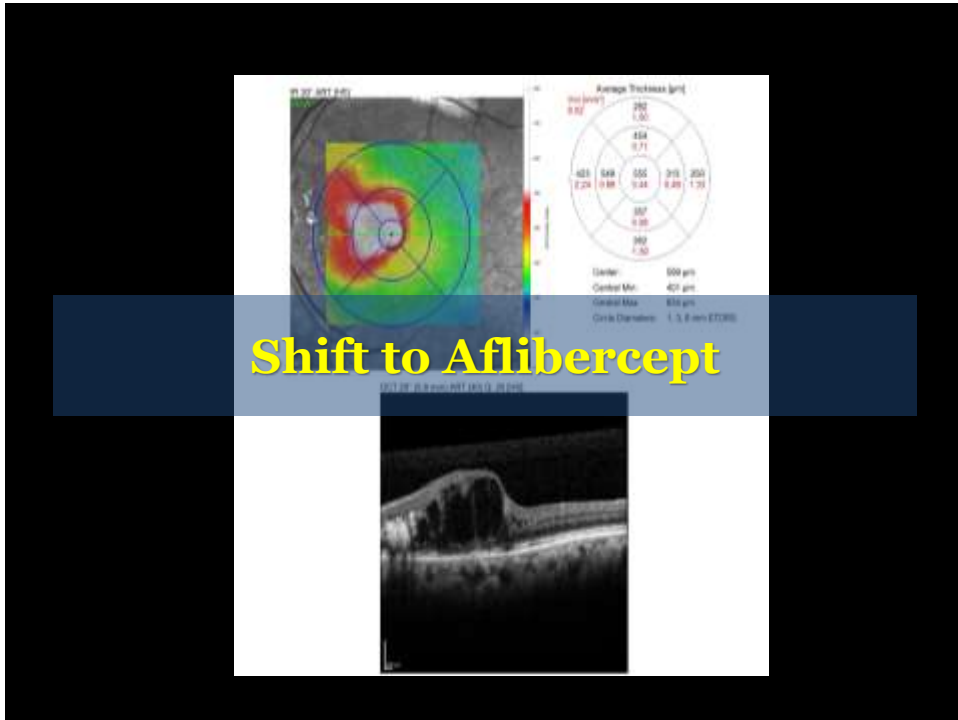
<b>O/E:</b>	<b>OD.</b>	<b>OS.</b>
<b>V/A</b>	<b>0.7</b>	<b>0.05</b>
<b>Cornea</b>		<b>Clear</b>
<b>A.C</b>		<b>NDC</b>
<b>Lens</b>	<b>N++</b>	<b>PC IOL</b>
<b>EOMs</b>	<b>Freely Acting in All Directions</b>	
<b>IOP</b>	<b>14</b>	<b>16 mm hg</b>

## Non-Responder ??









**IV-Ranibizumab  
+  
MicoPulse Laser**

