



# Adventures Through Medical Retina Cases

Karim A Raafat  
Professor of Ophthalmology  
Cairo University

Male patient, 54 - years - old , recent drop of vision  
BCVA 0.1 (OD) , 0.9 (OS)  
P/H Anti-VEGF (x 3)

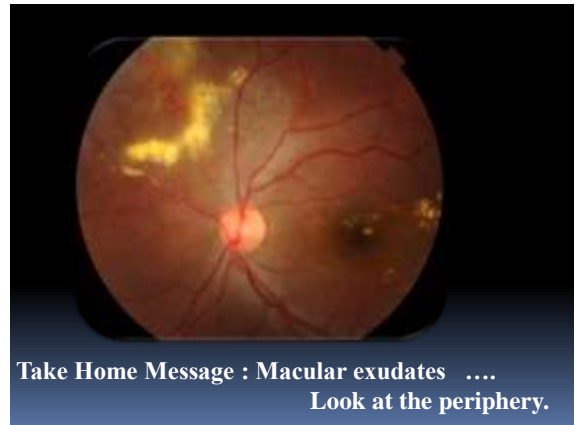
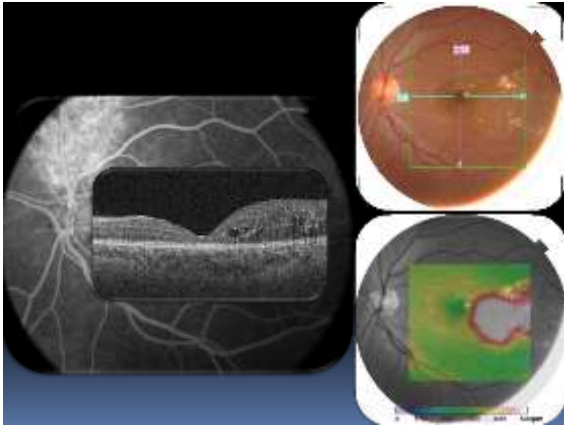
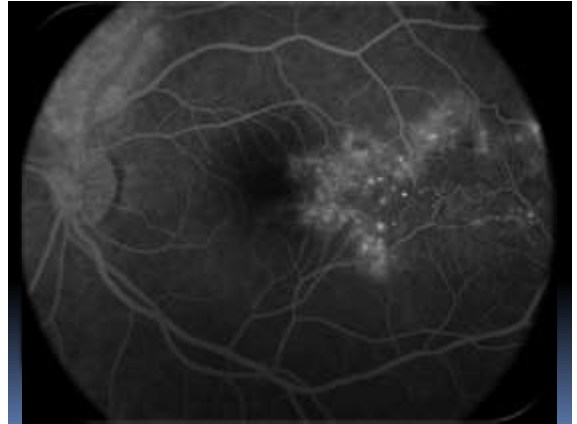
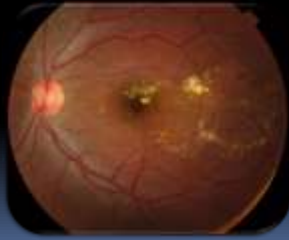Q : Provisional Diagnosis : WET AMD ??

Q : Why there is No intra retinal edema nor sub retinal fluid ??

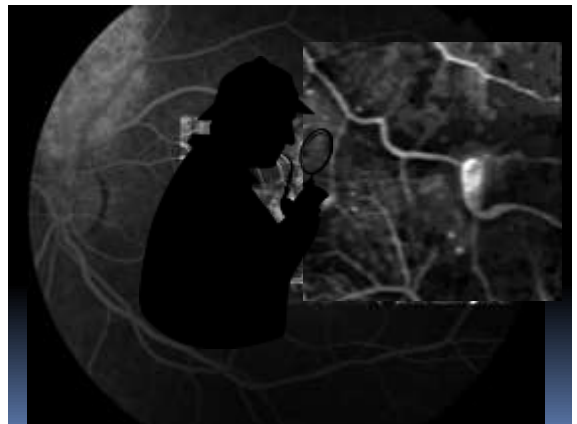
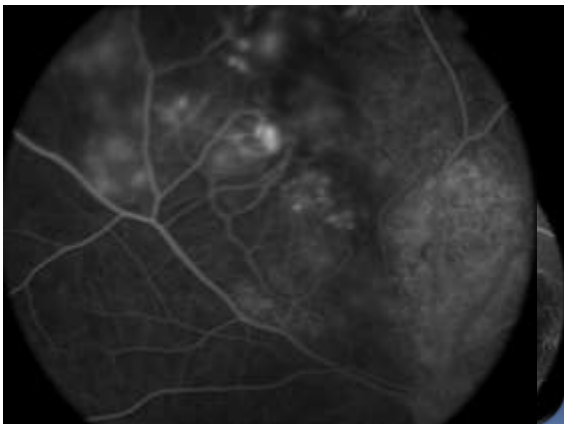
Fellow eye



23- years -old , male  
 C/O : drop of vision (OS)  
 BCVA : 6/6 (OD) 6/36 (OS)  
 Ant. Segment : within normal  
 Medial History : unremarkable , No D /No HTN



Take Home Message : Macular exudates ....  
 Look at the periphery.



### Coats' Disease & Leber's Multiple Miliary Aneurysms



George Coats  
Scottish Ophthalmologist  
1876 - 1915

1908 : Idiopathic retinal telangiectasia , intra - and sub retinal exudates and exudative RD  
80 % Males , 1<sup>st</sup> Decade , 95 % Unilateral  
NO associated ocular or systemic conditions

### Leber's Multiple Miliary Aneurysms



Theodore Leber  
German Ophthalmologist  
1840 - 1917

1915 : Milder form of Coats'  
Lacks massive sub retinal exudation

Thank  
YOU